



# Trigeminal autonomic cephalgias

Rafael Benoliel

*British Journal of Pain*  
6(3) 106–123  
© The British Pain Society 2012  
Reprints and permission:  
sagepub.co.uk/  
journalsPermissions.nav  
DOI: 10.1177/2049463712456355  
bjp.sagepub.com



## Summary points

1. Trigeminal autonomic cephalgias (TACs) are headaches/ facial pains classified together based on:
  - a suspected common pathophysiology involving the trigeminovascular system, the trigeminoparasympathetic reflex and centres controlling circadian rhythms;
  - a similar clinical presentation of trigeminal pain, and autonomic activation.
2. There is much overlap in the diagnostic features of individual TACs.
3. In contrast, treatment response is relatively specific and aids in establishing a definitive diagnosis.
4. TACs are often presentations of underlying pathology; all patients should be imaged.
5. The aim of the article is to provide the reader with a broad introduction to, and an overview of, TACs. The reading list is extensive for the interested reader.

## Keywords

Cluster headache, paroxysmal hemicrania, SUNCT, hemicrania continua, headache, facial pain

## Introduction

Trigeminal autonomic cephalgias (TACs) are primary headaches with a common clinical phenotype consisting of trigeminal pain with autonomic signs, which may include lacrimation, rhinorrhoea and miosis. The International Headache Society's (IHS) classification includes cluster headache, paroxysmal hemicrania and short-lasting, unilateral, neuralgiform headache attacks with conjunctival injection and tearing (SUNCT).<sup>1</sup> Hemicrania continua, although classified separately, is thought to be related to TACs and will be briefly described. There is consistent evidence that patients with TACs continue to suffer from delayed diagnosis and inappropriate treatment, in spite of the involvement of secondary care specialties.<sup>2</sup> It is therefore imperative that we improve the clinical recognition of these entities. The IHS classification system is indispensable for the clinician and will assist in reading this article; it can be viewed at <http://ihs-classification.org/en/>.

Secondary TACs usually have no 'typical' clinical profile and often present with characteristic TAC, including alternating attack and attack-free periods, and excellent response to TAC-specific treatments.<sup>3,4</sup> Neuroimaging, and careful physical and neurological

evaluation, should therefore be considered in all patients with TAC or TAC-like syndromes,<sup>5</sup> particularly in those with atypical presentation.<sup>3,6,7</sup>

TAC pathophysiology shares certain features and these will be reviewed here.

## Pathophysiology of TACs

This section deals with TACs in general, although there are subtle differences between them. The current pathophysiological model attempts to explain the three major features of TACs: trigeminal pain, rhythmicity (particularly in cluster headache) and autonomic signs.

---

Department of Oral Medicine, The Hebrew University-Hadassah Faculty of Dental Medicine Founded by the Alpha Omega Fraternity, Jerusalem, Israel

### Corresponding author:

Rafael Benoliel, Department of Oral Medicine, The Hebrew University-Hadassah Faculty of Dental Medicine, Founded by the Alpha Omega Fraternity, Jerusalem, 91010, Israel  
Email: benoliel@cc.huji.ac.il

## Trigeminal pain

The debate over a peripheral versus a central origin of pain is likely to continue. The predominant factor probably depends on which TAC is being examined, but in primary TACs the prevalent opinion is that central components prevail. Moreover, certain features are not easily explained by a peripheral mechanism: gender predilections, unilaterality of the symptoms, sleep association and, particularly in cluster headache, the circadian rhythmicity of attacks.

*Trigeminovascular system.* The distribution of pain in TACs largely implicates activity of the trigeminal and upper cervical nerves. Central to the pathophysiology of neurovascular headaches is the trigeminovascular system; trigeminal nerve activation can explain pain and may initiate some of the autonomic manifestations.

A perivascular neurogenic inflammatory process<sup>8</sup> of the internal carotid artery in its bony canal or increased intraocular pressure within the confines of the eye may lead to pain in cluster headache. An orbital 'vasculitis' has been suggested in the aetiology of chronic paroxysmal hemicrania (CPH) and cluster headache. Such neuronal activity (with neuropeptide release) was thought to originate from dilated blood vessels that stimulate trigeminal nociceptors directly. This hypothesis has been refuted by research findings, including continuing pain even when vasodilation is prevented.<sup>9</sup> Vascular changes are therefore considered an epiphenomenon of antidromic activation of the trigeminovascular system.

Increased levels of calcitonin-gene-related peptide (CGRP), nitric oxide (NO) and vasoactive intestinal peptide (VIP) in the cranial circulation in TACs indicate activity of the trigeminal and parasympathetic nerves.<sup>10,11</sup> Moreover, successful treatment with indomethacin or oxygen administration normalizes levels of both CGRP and VIP in CPH and reverses the elevation of CGRP in cluster headache.<sup>12</sup> Curiously, pain will often continue following trigeminal nerve sectioning. Indeed it is interesting to note that many patients with cluster headache complain of pain outside trigeminal dermatomes. Together this may suggest that pain in cluster headache is not solely of trigeminal origin or is central in origin.

Sympathetic dysfunction is indicated by ptosis and miosis. These may be secondary to neuropathic effects of carotid edema on the sympathetic plexus or may signify a generalized sympathetic dysfunction. Indeed, a dysfunction in the central control of the autonomic system in cluster headache and paroxysmal hemicrania has been proposed. However, cluster headache may occur with no autonomic signs, and conversely typical cluster headache autonomic signs

occur with no pain;<sup>13,14</sup> this would suggest that autonomic dysfunction is not a driving force in cluster headache.

*'Neuropathic' mechanisms.* Attacks of paroxysmal hemicrania and SUNCT may be mechanically activated, often with a short latency, implicating neurogenic transmission. In paroxysmal hemicrania, 10% of cases report a clear trigger mechanism, usually neck movement, and patients with SUNCT demonstrate trigeminal neuralgia-like triggers.<sup>15</sup> Successful microvascular decompression in cluster headache suggests that neuropathic mechanisms may be involved.<sup>16</sup>

## Rhythmicity

The periodicity and sleep association in TACs suggests involvement of central sites involved in the control of the human 'biological clock'. In humans these are located in the suprachiasmatic nucleus, situated in the anterior part of the hypothalamus dorsal and above the optic chiasm.<sup>17</sup> Early neuroimaging studies showed structural and functional hypothalamic changes in TACs, particularly cluster headache.<sup>18,19</sup> However, some of these changes are not specific to TACs and are found in craniofacial and spinal pain syndromes.<sup>18</sup> This is not surprising since the hypothalamus has connections with the medullary dorsal reticular nucleus: a supraspinal system that gives origin to a descending projection that facilitates pain perception. The ventromedial hypothalamus is also active in nociceptive pathways. Additionally, the hypothalamus has functional connections with the parasympathetic pterygopalatine ganglion and the sensory trigeminal nuclei.

In cluster headache, hypothalamic activation by imaging has been inconsistent in appearance, location and laterality.<sup>9</sup> This may be because of methodological issues: studies rely on accurate stereotactic positioning relative to the hypothalamus, which is a small structure with multiple areas responsible for a multitude of functions. These areas are imaged with what are still rather relatively imprecise implements.<sup>18</sup>

The endocrinology of cluster headache is a fascinating area.<sup>20</sup> The neuropeptide hypocretin is found exclusively in the posterolateral hypothalamus, an area highly associated with cluster headache. Moreover, functions of hypocretin include pain modulation<sup>21</sup> and regulation of the sleep-wake cycle. Hypothalamic regulation of the endocrine system also involves rhythmic and phasic homeostatic modulation of the hypophyseal hormones and melatonin. The principal external stimulus for the rhythmic production of melatonin is light intensity. This input reaches the suprachiasmatic

nucleus of the hypothalamus via a direct pathway from the retina. Studies of melatonin in cluster headache patients found that 24-h production was reduced and its pattern altered during the cluster period compared with normal subjects.<sup>22</sup> This finding links to descriptions of cluster headache variations with daylight hours, partly explaining the seasonal timing of active cluster periods.

Thus, the hypothalamus is in a prime position to potentially initiate or modulate TACs. Results of deep brain stimulation suggest that the hypothalamus may have a role in terminating cluster headache attacks.<sup>23</sup> However, the precise role of the hypothalamus in cluster headache is still the source of some controversy and we must interpret the current and future data very carefully.

## Autonomic signs

### *Trigeminoparasymphathetic reflex*

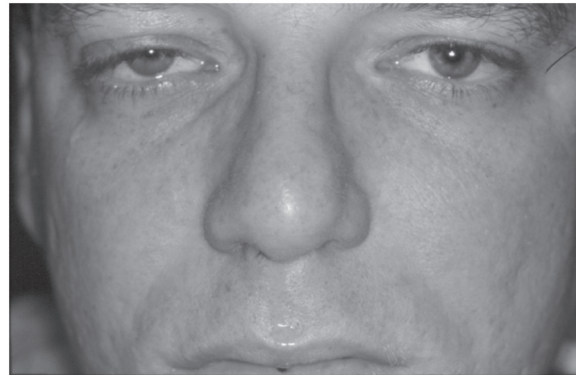Cranial parasympathetic fibers arise in the superior salivatory nucleus and innervate part of the craniofacial structures. Postganglionic fibres project to specific craniofacial targets such as the lacrimal, nasal mucosa and salivary glands as well as the craniofacial vasculature. Independent parasympathetic activity induces lacrimation and rhinorrhoea as observed in TACs.

Painful experimental stimuli in areas innervated by trigeminal nerve divisions 1 and 2 will cause autonomic signs similar to those observed in TACs.<sup>24</sup> These effects are widely considered secondary to initiation of a parasympathetic reflex through trigeminal nerve activation: the trigeminoparasymphathetic reflex (TPR). Elevated plasma VIP levels confirm activity of the parasympathetic system in cluster headache and CPH.<sup>12,25</sup> Experimental data suggest a role for hypothalamic modulation of the TPR<sup>26</sup> and it has been proposed that the TPR may be pathologically disinhibited in TACs. The presence of autonomic signs is consistent across TACs but the intensity and frequencies reported differ (see Table 1).

Taken together, current data suggest that cluster headache and other TACs are conditions whose pathophysiological basis is in the central nervous system (CNS) that drives the initiation of the clinical phenotype. The involvement of peripheral mechanisms is unclear.

## Cluster headache

Cluster headache is the archetypal TAC, with severe pain and major autonomic activation.<sup>1</sup> In Figure 1, the patient with cluster headache has right-sided ptosis, miosis, and profuse lacrimation and rhinorrhoea.



**Figure 1.** Photograph of a patient with cluster headache during a right-sided painful attack. Note the ipsilateral ptosis and miosis. Additionally there is obvious ipsilateral lacrimation and rhinorrhoea [see upper lip]<sup>27</sup>. Reprinted from Benoliel R and Sharav Y. Trigeminal autonomic cephalgias (TACs). In: Y Sharav and R Benoliel (eds) *Orofacial pain and headache*. Edinburgh: Mosby Elsevier, 2008; pp.223–254 with permission.

A unique feature of cluster headache is the distinctive circadian and circannual periodicity in the episodic form. Episodic cluster headache commonly occurs at least once daily for a period of weeks, at the same time of day or night.<sup>28</sup> Active periods (6–12 weeks) are followed by a temporary remission that may last from weeks to years (12 months). Attacks tend to be shorter and less severe at the beginning and towards the end of each cluster period. At its initial onset, cluster headache active periods are seasonal, occurring around spring or autumn.<sup>27</sup> Correlation between changes in daylight hours or geographical relocation and cluster headache occurrence and frequency has also been noted.

There are two distinct temporal presentations of cluster headache; most (80–85%) suffer from the episodic type characterized by at least two cluster periods separated by pain-free periods of  $\geq 1$  month over 7–365 days.<sup>1</sup> In chronic cluster headache, repeated attacks recur over more than a year without remission or, with remission, periods lasting less than 1 month. Interictal pain may also be present between attacks or between clusters.<sup>29</sup> Of the 15% of patients with chronic cluster headache, in two-thirds it usually begins as such and in the remainder evolves from the episodic form. Up to half of patients with chronic cluster headache report transition to an episodic pattern.<sup>30</sup> Over the course of the disease, attack duration tends to lengthen in both episodic and chronic cluster headache.

Surprisingly for such a dramatic syndrome, the interval until final diagnosis was 3–6 years: 34–45% had consulted a dentist and 27–33% an otolaryngologist before accurate diagnosis.<sup>2,29,31–33</sup> Among factors that increased the diagnostic delay were referral patterns, the presence of migrainous features, an episodic attack pattern and a young age at onset.

**Table 1.** Accompanying signs and treatment response in unilateral headaches with autonomic signs.

Parameter	Migraine	Cluster headache	Chronic paroxysmal hemicrania	SUNCT/SUNA	Hemicrania continua
Autonomic signs	+	+++	++	+++	+/-^
Lacrimation	41%#	84–91%	62%	+	12–53%
Conjunctival injection	#	58–77%	36%	+	12–32%
Nasal congestion	14%*	48–72%	42%	+	9–21%
Rhinorrhoea	*	43–72%	36%	+	10–12%
Flushing	+	–	–	–	2.9%
Ptosis/miosis	–	57–74%	–	–	2–28%
Ocular+nasal	46%**				
Systemic signs	> 80%	24–56%	–	–	50%
<b>Treatment response</b>					
Analgesics	+	+/-	–	–	–
Carbamazepine	–	–	–	–	–
Valproic acid	+	+/-	–	–	–
Lamotrigine	–	–	–	+	–
Indomethacin	–	–	++	–	++
Sumatriptan	++	++	+/-	–	–
Amitriptyline	+	–	–	–	–
Steroids	–	+	–	–	–
Beta-blockers	+	–	–	–	–
Ca <sup>2+</sup> -blockers	+	+	+ (cases)	–	–

SUNA, short-lasting, unilateral, neuralgiform headache attacks with cranial autonomic features; SUNCT, short-lasting, unilateral, neuralgiform headache attacks with conjunctival injection and tearing.

Autonomic signs: + = infrequent, ++ = frequent, +++ = very frequent, +/- = rare. Autonomic signs in HC refer to baseline and exacerbation studies. ^ increased during exacerbations

# specific ocular symptoms and \* specific nasal symptoms: numbers for migraine were reported together.

\*\*combination of all ocular and nasal symptoms in migraine patients.

Treatment response: - = none, +/- = inconsistent response, + = response, ++ = high response rates, cases = relies on case reports.

**Table 2.** Clinical features in unilateral headaches with autonomic signs.

Parameter	Migraine	Cluster headache	Chronic paroxysmal hemicrania	SUNCT	Hemicrania continua
<b>Demographics</b>					
Age at onset	20–30	30–40*	30–40	40–50	30–40
Gender ratio (M:F)	1:3	3:1	1:1	1.5:1	1:2
Family history	60%	7%	None	?	–
<b>Sleep association</b>					
Awakens subjects	REM, III/IV	REM	REM	–	+
Time/frequency	Yes	Yes	Yes	No	Yes
Changes sides	Early morning	51%	33%	< 2%	30–50%
Intensity	Yes	May	Rare	No	No
Remission	++	+++	++	++++	+/>++
Triggering	Pregnancy	Months to years	Unusual	+/>–	–
<b>Triggering</b>					
Touch	No	No	No	Yes	No
Neck	No	No	Yes (10%)	Yes	No
Alcohol	Delayed	Yes	inconsistent	inconsistent	Yes
Others (e.g. foods/stress)	Yes	No	No	No	Yes

REM, rapid eye movement; SUNCT, short-lasting, unilateral, neuralgiform headache attacks with conjunctival injection and tearing.

\*onset in women differs, ? = unclear, ++ = severe

+++ = very severe

++++ = excruciating

+/>++ = moderate/severe

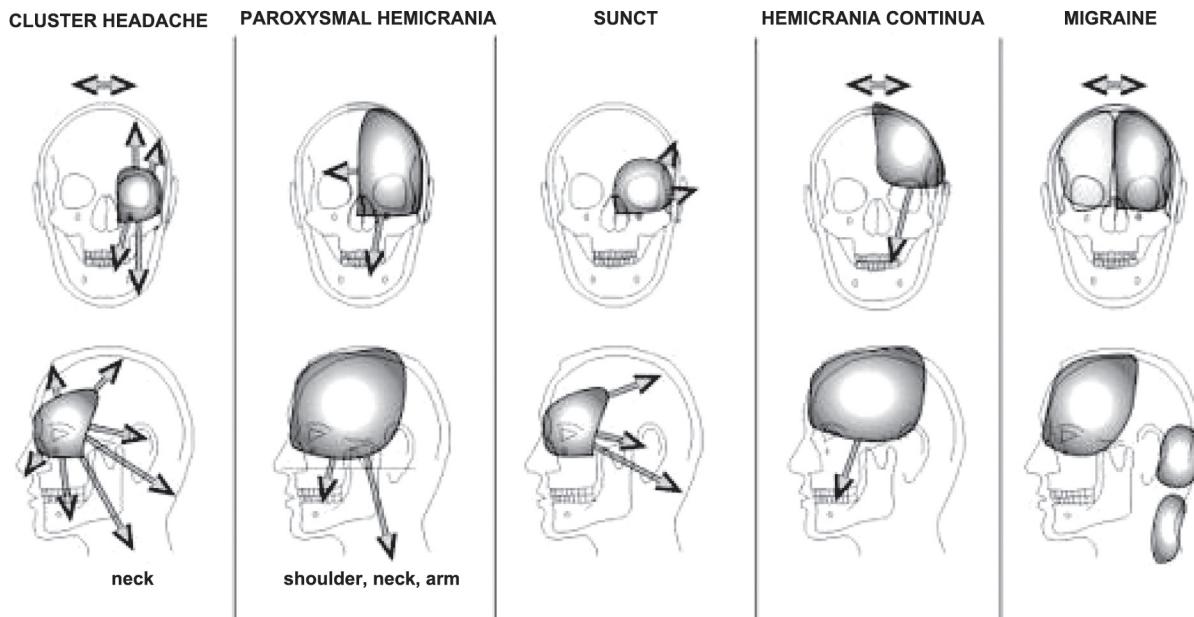


### Cluster headache attacks

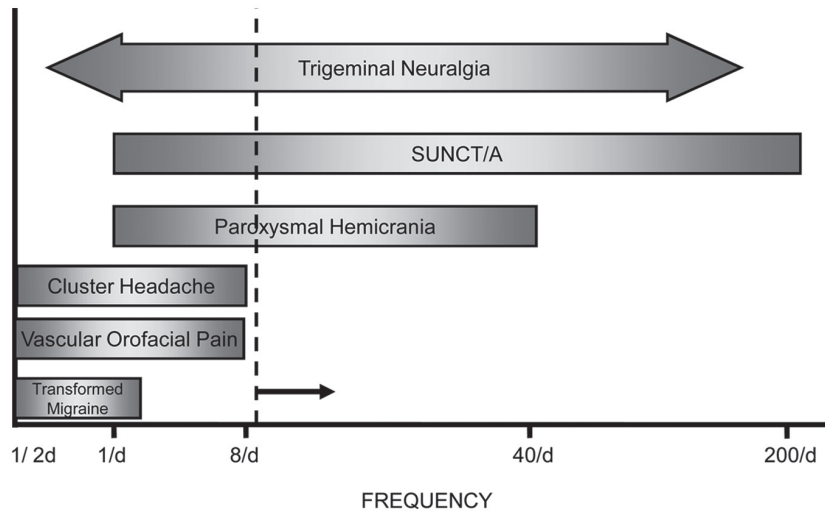
The following summary maintains the essential core criteria as described by the IHS, but is embellished with information gleaned from the literature. The IHS requires at least five attacks that meet the criteria outlined (further details in Tables 1 and 2).

### Summary of features of cluster headache

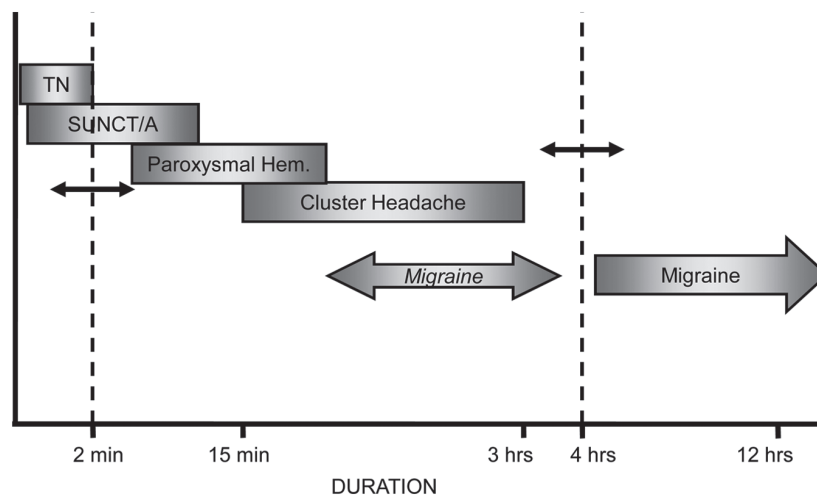
- Periorbital or ocular<sup>27</sup> pain (see Figure 2).
  - ‘Lower’ and ‘upper’ subtypes of cluster headache exist:
    - ‘upper cluster headache’ also forehead, temporal and parietal regions;<sup>34</sup>
    - ‘lower cluster headache’ also temporal, and suboccipital with radiation to the teeth, jaws, neck,<sup>34</sup> teeth and cheeks.<sup>29,35</sup>
- Unilateral pain.
  - 20% of cases may change sides.<sup>27</sup>
  - Attacks alternate sides; more common between clusters than between attacks in the same cluster.<sup>27</sup>
- Excruciating severity.
  - Rated as 8–10 on a 10-point visual analogue scale (VAS) by > 85% of patients, and some patients even report considering suicide.<sup>27</sup>
- Pain is non-specific and may vary between bouts: either throbbing or boring, burning, stabbing, piercing.<sup>36</sup>
  - ‘Hot poker’ or a ‘stabbing’ feeling in the eye.<sup>35</sup>
  - Sudden jabs of intense pain are often felt and may be an integral part of some cluster headache variants.
- Accompanied by at least one of these ipsilateral autonomic phenomena/signs:
  - conjunctival injection/lacrimation;
  - nasal congestion/rhinorrhoea;
  - eyelid oedema;
  - forehead/facial sweating;
  - miosis and ptosis;
  - restlessness (not a local autonomic sign but so frequent (> 80%) it has been included as a diagnostic criterion).
- Patients appear agitated, continually move around and change body position, particularly during severe attacks,<sup>37</sup> in sharp contrast to the quiet-seeking behaviour observed in migraine.
- Lasts 15–180 minutes.
  - Peak intensity is usually rapid, within 3 minutes, but may take 9–10 minutes.<sup>36</sup>
  - Long-lasting attacks are rare but may last from 3 to 48 hours.<sup>29</sup>
  - Frequency of one every 2 days to eight per day (see Figures 3 and 4).



**Figure 2.** Pain location in TACs and migraine. TACs are characterized by orbital and periorbital pain. In paroxysmal hemicrania and hemicrania continua there are large adjacent areas affected. Migraine is largely unilateral but may be bilateral in up to 30% of cases (this has been marked by a lighter-shaded area contralaterally). The two-headed arrow above the diagram indicates side shift, which occurs in specific headache.



**Figure 3.** Frequency in neurovascular headaches and trigeminal neuralgia. The International Headache Society<sup>1</sup> clearly defines pain frequency but there is considerable overlap. The short-lasting headaches (trigeminal neuralgia, SUNCT, paroxysmal hemicrania) are very frequent (more than eight per day, dotted line) with considerable overlap. Similarly, the long-lasting headaches overlap in the frequency of attacks. Trigeminal neuralgia (shown in double arrow) is often triggered but is usually of high frequency. SUNCT/A, short-lasting, unilateral, neuralgiform headache attacks with conjunctival injection and tearing/autonomic signs.



**Figure 4.** Duration in neurovascular headaches and trigeminal neuralgia. The International Headache Society<sup>1</sup> clearly defines pain duration but there is considerable overlap. Duration overlap occurs particularly in headaches lasting from 2 minutes to 4 hours; beyond these limits (dotted lines) diagnosis is relatively limited. It is important to note that migraines may occasionally last less than 4 hours (migraine in double arrow) and cluster headache has been reported to last up to 48 hours.

Hem, hemicrania; SUNCT/A, short-lasting, unilateral, neuralgiform headache attacks with conjunctival injection and tearing/autonomic signs; TN, trigeminal neuralgia.

### Additional features

Nocturnal cluster headache is particularly prevalent (51–73%) and pain awakens patients 90 minutes after sleep initiation, at about the onset of rapid eye movement (REM) sleep.<sup>35</sup> An association between episodic cluster headache and REM sleep has been shown; less so with chronic cluster headache.<sup>38</sup> Sleep deprivation,

resulting from high-frequency attacks, leads to early-onset REM, often triggering further attacks. Patients with cluster headache demonstrate a significantly greater percentage of obstructive sleep apnoea.<sup>39</sup> Treatment of one entity frequently improves the other.

Alcohol, even in small amounts, may precipitate cluster headache attacks during active cluster periods, so patients tend to avoid alcohol during

active periods.<sup>40</sup> Some patients with cluster headache, particularly those in whom it evolves into chronic cluster headache, have a history of high alcohol and tobacco consumption.<sup>41</sup>

In patients with cluster headache, specific symptoms may occur minutes to days before pain onset.<sup>27</sup> Local prodromes include autonomic signs and mild pain or non-painful sensations in the area that subsequently becomes painful.<sup>42</sup> Additionally, blurred vision, sensitivity to smells, nausea, dyspepsia, hunger, irritability, tiredness and tenseness are described.<sup>42</sup> Premonitory symptoms may predict cluster headache days before onset and are reported in 40% of cluster headache cases. These may be similar to those experienced by migraineurs and include body numbness, neck pain, irritability, lethargy and sleepiness.<sup>42</sup> 'Aura-like' symptoms are reported by 14% of cases.<sup>43</sup>

### Autonomic signs

Lacrimation is the most frequent autonomic sign, occurring in up to 90% of cases.<sup>35</sup> Autonomic signs are particularly common and pronounced in cluster headache, whereas in other TACs they may be subtler and rarer (see Table 2). Autonomic signs are transient and resolve with the headache, but rarely ptosis and miosis (partial Horner's syndrome) may persist. Intensity of autonomic signs may be related to pain severity; i.e. in patients with weak cluster headache attacks, mild or no autonomic signs may occur.<sup>44</sup>

Migrainous features are common in cluster headache including photophobia (56%), phonophobia (43%), nausea (41%) and vomiting (24%).<sup>45</sup> Interestingly, these (phono/photophobia) are largely unilateral whereas in migraine they are bilateral.<sup>46</sup> Cluster headache associated with transient hemiparesis has been reported, also accompanied by visual symptoms, photophobia, phonophobia and nausea.<sup>45</sup> This clinical phenotype is strikingly similar to side-locked migraine.

### Secondary cluster headache

Symptomatic cluster headache has been described as a result of rare pathologies, including vascular lesions, and even multiple sclerosis.<sup>27</sup> Cluster headache secondary to post-traumatic head injury has also been described.<sup>47</sup>

In patients with pituitary tumour, 4% were found to suffer from cluster headache and 10% suffered TAC-like headaches.<sup>48</sup> Careful review of such cases reveals that 'tell-tale' signs were often present in the neurological examination and in symptomatology of the headaches,<sup>49</sup> although, as stated, secondary TACs are often typical.<sup>7</sup>

### Epidemiology

Cluster headache typically appears between the ages of 20 and 29 years<sup>28</sup> and is more common than previously thought. Based on pooled epidemiological data, the closest approximation to actual cluster headache lifetime incidence is proposed to be 53 cases per 100,000<sup>50</sup> but it may reach 120–300/100,000 population<sup>51</sup> and seems to affect men more than women.

### Genetics

The genetics of cluster headache are not entirely clear. However, first-degree relatives of patients with cluster headache are 14–48 times and second-degree relatives 2–8 times more likely to have cluster headache than the general population.<sup>9</sup> Cluster headache is likely to have an autosomal dominant gene with low penetrance, present in 3–4% of males and 7–10% of females, but autosomal recessive or multifactorial inheritance may also occur.<sup>9</sup>

### Cluster headache treatment (see Tables 3–5)

A combination of patient education, symptomatic treatment and prophylactic regimens are the essential cornerstones of successful treatment in all headaches.<sup>52</sup> Based on attack patterns patients should be instructed to avoid daytime naps, alcoholic beverages and other triggers such as volatile substances (e.g. paints). Altitude hypoxemia may trigger an attack during active periods but may be pharmacologically prevented.<sup>52</sup> A clear explanation of mechanisms, treatment options and prognosis is essential. Depending on the diagnosis, frequency and individual parameters, treatment may be abortive, transitional, prophylactic or surgical.<sup>53,54</sup>

- Abortive (first line):<sup>53</sup>
  - Rapid symptomatic relief with oxygen inhalation.<sup>53</sup>
    - Useful diagnostic test.
    - Higher flow rates (15 L/min) may be successful in previously resistant cases.<sup>55</sup>
  - Subcutaneous sumatriptan if medically fit.
- Transitional and prophylactic:<sup>53</sup>
  - Rapid transitional prophylaxis may be attained with corticosteroids for a limited period in selected patients.<sup>56</sup>
  - Long-term prophylaxis usually with verapamil<sup>52</sup> in both episodic and chronic cluster headache.
  - Topiramate as second-line therapy.
  - Although many side-effects, lithium carbonate may be considered.

**Table 3.** Selected abortive pharmacological treatment options for episodic cluster headache.

Agent	NNT	Dose	Comments	Side-effects
Oxygen (inhaled via face mask)	2.04	5–10 L/min 15 min, 15 L/min may be tried	First line but cumbersome Hyperbaric oxygen also efficacious but impractical	None
Sumatriptan	2.2	6–12 mg SC	First line, fast and efficacious. 12 mg as effective as 6 mg but with more side-effects Marginally less effective in chronic cluster headache	Contraindicated in cardiovascular disease Fatigue Nausea/vomiting Chest symptoms Skin reactions over puncture wound
	3.45	20 mg IN	Less effective but easier to use	Contraindicated in cardiovascular disease IN<SC
Zolmitriptan	5.0	5–10 mg IN	Limited efficacy, alternative to IN sumatriptan	Contraindicated in cardiovascular disease Better in episodic cluster headache
Dihydroergotamine	–	0.5–1 mg IN (bilateral)	Reduces severity but not frequency. Risk of rebound.	Contraindicated in cardiovascular disease. Do not use with a triptan
Lignocaine	–	1 ml of 4–10% solution applied IN on cotton pledget bilaterally	Pain is decreased but not enough studies. Needs to be inserted deep near pterygopalatine foramen	Bitter taste

IN, intranasal; NNT, number needed to treat; SC, subcutaneous < = less efficacious than.

**Table 4.** Prophylactic treatment of episodic cluster headache.

Agent	Target dose	Comments	Side-effects
Verapamil	160–480 mg/day (PO)	First-line treatment. Perform baseline and 6-monthly ECGs	Hypotension, bradycardia, heart block, dizziness and fatigue
Prednisone	80 mg (PO) Typical schedule: 80 mg first 2 days. Reduce by 20 mg every 2 days. Reduce to 10 mg/day for last 2 days	Good for initial and transitional therapy until, for example, verapamil takes effect. Prolonged use not recommended because of side-effects. Taper over 10–21 days	Increased appetite, nervousness, hyperglycaemia, insomnia, headaches
Topiramate	25–200 mg/day (PO)	Increase by 25 mg/day every 5 days	Cognitive effects, paraesthesias, dizziness
Valproic acid	600–2000 mg/day (PO)	Efficacious in patients with pronounced migrainous features. Monitor liver function	Nausea, dizziness, dyspepsia, thrombocytopenia
Gabapentin	900 mg/day (PO)	Few studies but promising results	Drowsiness
Melatonin	9–10 mg/day nocte (PO)	Few studies	None

ECG, electrocardiography; PO, per os.

**Table 5.** Treatment of chronic cluster headache.

Agent	Target dose	Comments	Side effects
Verapamil	360–480 mg/day (PO)	First-line treatment. Perform baseline ECG	Hypotension, bradycardia, heart block, dizziness and fatigue
Lithium carbonate	300–900 mg (PO)	Requires monitoring of renal and thyroid function, and of serum concentrations (best at 0.4–0.8 mEq/L)	Weakness, nausea, tremor, slurred speech, blurred vision. Side-effects greater than with verapamil

ECG, electrocardiography; PO, per os.



**Table 6.** Assessment of intractable cluster headache prior to surgery.

1. Reassess organic pathology
2. Reassess diagnosis versus other entities such as:
  - a. side-locked migraine
  - b. paroxysmal hemicrania
  - c. SUNCT
3. Review pharmacotherapy:
  - a. adequate monotherapy
    - i. Have the frontline drugs all been tested?
    - ii. Adequate dosing/duration?
  - b. adequate polytherapy as above?
4. Consider referral:
  - a. reassessment and diagnosis
  - b. for inpatient treatment with intravenous medication
5. Is the patient fit for neurosurgery:
  - a. medically?
  - b. psychologically?
6. Patients with strictly unilateral pain are best candidates:
  - a. Pain that has alternated sides carries a poorer prognosis
7. Explain carefully that surgical failure is a possibility and pain attacks, autonomic signs or both may continue

SUNCT, short-lasting, unilateral, neuralgiform headache attacks with conjunctival injection and tearing.

- Surgical:
- Deep brain stimulation only following careful appraisal<sup>23,53</sup> (Table 6), in:
  - medically resistant cluster headache, which occurs in 10–20% of patients
  - patients who respond to medical therapy but suffer intolerable side-effects.
- Ablative surgical intervention should be avoided. Consider as a last resort.

Note: It has traditionally been accepted that patients with cluster headache do not suffer from medication overuse headache. However, recent reports indicate that this is not the reality for both cluster headache and other TACs, and clinicians should monitor their patients carefully.<sup>57,58</sup>

Remission periods in many patients may increase with time and, beyond the age of 65–75, active cluster headache is rare.<sup>27</sup>

## Paroxysmal hemicrania

The first reported cases of paroxysmal hemicrania were of a continuous nature and were categorized as chronic paroxysmal hemicrania. Only a scant number (20%) of paroxysmal hemicranias behave episodically<sup>59</sup> and many of these eventually develop into a chronic form.<sup>60</sup> The following criteria maintain the criteria described by the IHS, but are elaborated with information garnered from the literature. The IHS requires at least 20 attacks that meet the criteria outlined.

## Summary of paroxysmal hemicrania features

- Unilateral, severe orbital or periorbital pain:
  - rarely may become bilateral;<sup>61</sup>
  - also temporal, periauricular, maxillary and rarely occipital areas;<sup>59,62</sup>
  - referral to the shoulder, neck and arm is quite common;<sup>62</sup>
  - strong pain may cross the midline;
  - the vast majority of attacks do not change sides.<sup>59</sup>
- Lasts 2–30 minutes:
  - more usually 13–29 minutes, but may last nearly an hour;
  - pain onset is rapid and mostly peaks in less than 5 minutes.<sup>59</sup>
- Sharp and excruciating:<sup>59</sup>
  - also throbbing, stabbing, sharp or boring.<sup>59,63</sup>
- Accompanied by at least one of these ipsilateral autonomic phenomena/signs:
  - conjunctival injection/lacrimation;
  - nasal congestion/rhinorrhoea;
  - eyelid oedema;
  - forehead/facial sweating;
  - miosis and ptosis.
- More than five attacks daily
  - usually 8–30 attacks per 24 h.<sup>60</sup>
- One to five attacks per 24 h have also been reported:<sup>59</sup>
  - more recently a seasonal pattern of attacks in patients with paroxysmal hemicrania has been described;<sup>64</sup>

- the temporal similarity to cluster headache behaviour has led to the term ‘modified cluster pattern’;<sup>62</sup>
- 30% report REM-related<sup>65</sup> nocturnal attacks that wake.<sup>60</sup>
- Absolute response to indomethacin.

### Additional features

Autonomic signs may occur bilaterally but are more pronounced on the symptomatic side. The most commonly seen are ipsilateral lacrimation, nasal congestion, conjunctival injection and rhinorrhoea.<sup>63,66</sup> Pain in paroxysmal hemicrania is not considered secondary to autonomic activation, as pain continues in spite of these phenomena being blocked.<sup>67</sup> In patient series, one ‘migrainous feature’ was reported in nearly 90% of cases.<sup>59,68</sup>

### Epidemiology

Paroxysmal hemicrania is rare; its prevalence has been estimated to be 2–20 per 100,000.<sup>51,69–71</sup> Initially cases were largely female but as more cases are reported a 1:1 ratio between male and female sufferers is approximated.<sup>59,70,72</sup>

Mean age at onset is usually 34–41 years, but children aged 6 and adults aged 81 years have been reported with an average illness duration of 13 years.<sup>59,60,73</sup> The episodic form is considered to have an earlier mean age at onset (27 years) than the chronic form (37 years).<sup>60</sup>

### Secondary paroxysmal hemicrania

Malignancy, CNS disease and benign tumours have been implicated in secondary paroxysmal hemicrania.<sup>6</sup> A case of parotid gland epidermoid carcinoma with cerebral metastasis causing paroxysmal hemicrania has been reported.<sup>74</sup> In two literature reviews,<sup>6,60</sup> systemic diseases were common in paroxysmal hemicrania; cases require careful work-up, including imaging.<sup>75</sup>

### Treatment

The response of paroxysmal hemicrania to indomethacin is absolute but the mechanism is poorly understood and it seems it is not entirely dependent on inhibition of cyclo-oxygenase activity. However, indomethacin has inhibitory effects on the central nociceptive system and has also been shown to reduce regional cerebral blood flow (rCBF) in experimental animals and humans.

Most cases respond within 24 hours, but 3 days at 75 mg followed, if needed, by 150 mg for a further 3 days is recommended as trial therapy;<sup>76</sup> persistently high dosage requirements may indicate an underlying pathology. Prognosis in paroxysmal hemicrania is good and long-term remission has been reported.<sup>77</sup> Indomethacin-resistant paroxysmal hemicrania may respond to topiramate.<sup>5,78,79</sup> Further alternatives include calcium channel blockers, naproxen or carbamazepine.<sup>5,54,58</sup> Acetazolamide, a diuretic with anti-convulsant properties, reduces intraocular pressure and is partially effective in paroxysmal hemicrania.<sup>80</sup> A summary of therapies for paroxysmal hemicrania, SUNCT and hemicrania continua is shown in Table 7.

### Short-lasting, unilateral, neuralgiform headache attacks with conjunctival injection and tearing (SUNCT)

SUNCT syndrome is a unilateral headache/facial pain characterized by brief paroxysmal attacks accompanied by ipsilateral local autonomic signs, usually conjunctival injection and lacrimation.<sup>81</sup> The similarities of this syndrome to trigeminal neuralgia are marked, particularly the triggering mechanism, and many believe SUNCT to be a variant of trigeminal neuralgia.<sup>82</sup>

The following features incorporate the criteria described by the IHS, but are embellished with data gleaned from the literature. The IHS requires at least 20 attacks that meet the criteria outlined below.

**Table 7.** Pharmacotherapy of paroxysmal hemicrania, SUNCT and hemicrania continua.

Headache	Drug of choice	Target dose (route)	Second line
Paroxysmal hemicrania	Indomethacin	75–225 mg/day (PO)	Other NSAIDs Verapamil Acetazolamide
SUNCT	Lamotrigine	100–300 mg/day (PO)	Gabapentin 900–2700 mg/day Topiramate 50–200 mg/day
Hemicrania continua	Indomethacin	25–300 mg/day (PO)	Other NSAIDs Piroxicam-beta-cyclodextrin

NSAIDs, non-steroidal anti-inflammatory drugs; PO, per os; SUNCT, short-lasting, unilateral, neuralgiform headache attacks with conjunctival injection and tearing.

### Clinical features

- Unilateral, classically described as ocular and periocular pain,<sup>1</sup> but may involve most head areas, e.g. temporal, auricular and occipital regions.<sup>72</sup>
  - Pain spreading across the midline or changing sides is rare.<sup>83</sup>
- Moderate to severe pain syndrome;<sup>83</sup> less severe than in trigeminal neuralgia.
- Pain is accompanied by ipsilateral conjunctival injection and lacrimation.
- Pain is usually stabbing or pulsating.
  - Sometimes electric or burning.<sup>83</sup>
- Pain lasts from 5 to 240 seconds.
  - Usually 15–120 seconds (mean 1 minute).
  - Longer-lasting attacks of 250, 600 seconds and even 2–3 hours have been reported.<sup>84</sup>
  - ‘SUNCT status’; pain lasting for most of the day for 1–3 days may rarely occur.<sup>85</sup>
  - Low-grade background pain/discomfort occurs.<sup>85</sup>
- Three patterns of attacks described:<sup>5,72</sup>
  - Classical single attacks.
  - Groups of a number of stabs/attacks.
  - ‘Saw tooth’ pattern with numerous stabs/attacks lasting minutes.
- The frequency of attacks is from 3 to 200 daily.
  - Inconsistent and irregular; average of 28/day (Figure 3).<sup>84</sup>
  - A bimodal distribution of attacks occurring in the morning and late afternoon has been observed.
  - Fewer than 2% of attacks occur at night.<sup>84</sup>
  - A ‘cluster-like’ pattern has been reported with active and inactive periods.<sup>81</sup>
  - A seasonal pattern has been reported in short-lasting, unilateral, neuralgiform headache attacks with cranial autonomic features (SUNA).<sup>86</sup>

### Additional features

Pain in SUNCT may be triggered by light mechanical stimuli in the areas innervated by the trigeminal nerve but with a short latency until pain onset.<sup>83</sup> Extratrigeminal triggers including neck movements have also been shown to precipitate attacks. Alcohol is not usually reported to worsen pain. In contrast to trigeminal neuralgia, no refractory period has been demonstrated in SUNCT; this is a major differentiating sign.<sup>83,87</sup>

By definition, SUNCT is accompanied by marked ipsilateral conjunctival injection and lacrimation that appear rapidly with onset of pain.<sup>1</sup> Nasal stuffiness and rhinorrhoea are common; sweating may accompany attacks but is rarer and often subclinical.<sup>81,88</sup>

### Short-lasting, unilateral, neuralgiform headache attacks with cranial autonomic features (SUNA)

This is a relatively novel diagnostic entity included in the IHS classification’s appendix. Essentially two criteria differentiate it from SUNCT: SUNA may be accompanied by any autonomic sign (nasal congestion, etc.), and attack duration has been extended to up to 10 minutes.<sup>1</sup> Attempts to refine these differential criteria will aid in diagnosis.<sup>5,58,72</sup>

### Epidemiology

It is possible that the clinical similarities with trigeminal neuralgia leads to the misdiagnosis of many cases.<sup>83</sup> SUNCT may therefore be more common than has been estimated based on the sparse case reports; some estimates suggest SUNCT/SUNA to be as common as paroxysmal hemicrania.<sup>51</sup> A male–female ratio of 7:1 was reported in 1998<sup>89</sup> but, with more female cases appearing, SUNCT is presently considered only slightly more common in males (male–female = 1.3:1).<sup>83,90</sup> Cases of all ages have been reported from childhood to old age with a mean onset at about 50 years.<sup>83,91</sup>

SUNCT occurring in siblings has recently been presented as ‘familial SUNCT’<sup>92</sup> and raises the possibility that SUNCT, together with migraine, cluster headache and possibly other TACs, will eventually be considered to be of genetic predisposition.

### Symptomatic SUNCT/SUNA

Diagnoses in symptomatic SUNCT/SUNA include brainstem infarction, cerebellopontine arteriovenous malformations, cerebellopontine astrocytoma or other tumours/cysts, cavernous hemangioma of the brainstem, cavernous sinus tumour, extraorbital cystic mass, vertebral artery dissection and neurofibromatosis.<sup>6,83,93,94</sup> Post-traumatic SUNCT, including eye trauma, has been reported.<sup>83</sup> Rare reports include SUNCT related to HIV and to osteogenesis imperfecta.<sup>6</sup> In a series of pituitary tumour patients, 5% were found to suffer from SUNCT.<sup>48</sup> These lesions are diagnosable with MRI and all SUNCT patients should therefore be referred for appropriate imaging.<sup>83</sup>

### SUNCT/SUNA treatment

SUNCT was originally known for its relative resistance to drug therapy.<sup>95</sup> Currently, lamotrigine has emerged as the treatment of choice and is recommended as initial and relatively successful therapy (~66%).<sup>5,96</sup> Initial dose should be 25 mg/day and increased very slowly, reaching

the target in 7 weeks or more. Dose increase is dependent on side-effects and therapeutic response is observed. Like cluster headache, SUNCT may also respond to steroids.<sup>95</sup> Anticonvulsant drugs may produce some improvement; SUNCT may initially be responsive to carbamazepine with some reduction in attack frequency and severity. There have been reports of SUNCT responding to treatment with relatively new anticonvulsants such as topiramate and gabapentin.<sup>5</sup> Gabapentin and topiramate are advised as second-line agents in patients who fail a trial of lamotrigine (Table 7).

Cases of SUNCT associated with trigeminal nerve compression and with a vascular malformation in the cerebellopontine angle have been reported.<sup>97</sup> Moreover, case reports of surgical microvascular decompression and percutaneous trigeminal ganglion compression for SUNCT as performed for trigeminal neuralgia have appeared.<sup>98</sup> A number of cases with SUNCT remain asymptomatic after microvascular decompression. Luckily, remissions have been observed and may last for several months.<sup>89,99</sup>

## Hemicrania continua

As hemicrania continua is further reported, this headache entity is increasingly considered a variant of TAC.<sup>1</sup> As in other TACs, hemicrania continua seems to be often misdiagnosed and mistreated; in a recent series, the time to correct diagnosis was 5 years.<sup>100</sup>

### *Clinical features of hemicrania continua*

- Unilateral headache for > 3 months.
  - Pain in the frontal and temporal regions and periorbitally.<sup>101</sup>
  - Although very rare, pain can also change sides.<sup>102</sup> Few bilateral cases.
- Daily and continuous pain.
- Severity is moderate (VAS 4.7).<sup>103</sup>
  - Characterized (74%) by fluctuations in pain severity.
  - Exacerbations are totally disabling in about 40% of patients.<sup>103</sup>
  - Exacerbations result in severe pain (VAS 9.3) lasting 30 minutes to 10 hours or even 2–5 days.<sup>27,103</sup>
  - During exacerbation, hemicrania continua is almost indistinguishable from migraine.<sup>103</sup>
  - Patients may report a sharp pain similar to the condition of ‘jabs and jolts’.<sup>103</sup>
  - Some patients (18%) describe a distinct ocular sensation mimicking a foreign body (e.g. sand) that may accompany or precede the headaches.<sup>27</sup>

- Pain is throbbing (one-third of cases); may appear as pain intensity increases.<sup>27,103</sup>
- Complete response to indomethacin.
- During exacerbations accompanied by at least one of these ipsilateral autonomic phenomena/signs:
  - conjunctival injection/lacrimation;
  - nasal congestion/rhinorrhoea;
  - miosis and ptosis.

### *Additional features*

Two forms of hemicrania continua have been described: remitting and continuous. The remitting form is characterized by headache that can last for some days followed by a pain-free period lasting from 2 to 15 days. This pattern is initially present in about half of the patients; in the rest pain is continuous from its onset.<sup>27,103</sup> One-third of remitting cases become continuous following a mean duration of 7.8 years.<sup>27,103</sup> Nocturnal attacks were reported in up to half of patients and some patients report that, if they awakened for other reasons, the pain was invariably present.<sup>27,103</sup>

A variety of factors such as bending over, menses, strong odours and stress have been reported to provoke or worsen the pain.<sup>27,103</sup> These are reminiscent of migraine but are not consistent features of hemicrania continua. Some cases may clearly identify alcohol as a provoking or aggravating factor.<sup>27,103</sup>

Hemicrania continua is not usually accompanied by notable pathology or other abnormalities.<sup>27</sup> Most published cases of hemicrania continua with computerized scanning of the head, neurological and other physical examination, haematology and serum biochemistry were all normal. Cases of hemicrania continua secondary to pathology or systemic disease have been reported.<sup>6</sup>

There is usually a paucity of autonomic signs in hemicrania continua. However, during exacerbation autonomic signs commonly appear singly or in various combinations, but are still relatively mild. This strengthens the hypothesis that activation of autonomic signs is dependent on pain severity. The most common signs present in 30–40% of patients are photophobia, nausea, conjunctival injection, phonophobia and tearing.<sup>27</sup> During exacerbations, up to 60% of patients display qualities such as photophobia, phonophobia, nausea and, more rarely, vomiting.<sup>103</sup> Hemicrania continua with aura has also been described, further linking hemicrania continua to migraine pathophysiology.<sup>104</sup> More rarely (15–18%) nasal stuffiness or rhinorrhoea, vomiting or ptosis may also be reported.<sup>27</sup> These features establish the hemicrania continua phenotype as straddling both TACs and migraine.



## Epidemiology

Most cases reported are female (F:M ratio = 2–2.8:1), with a mean age at onset of 28–33 years (range 5–67 years).<sup>27,103</sup> There is no significant difference observed in mean age at onset between cases that had begun as remitting ( $32 \pm 2.8$  years) and those that had begun as continuous ( $34 \pm 2.6$  years).<sup>27</sup>

## Secondary hemicrania continua

Three cases of hemicrania continua complicated or caused by medication abuse have been reported.<sup>27</sup> Two abused ergotamine and one acetaminophen, and cessation of the drug eliminated or reduced headaches. Hemicrania continua secondary to a mesenchymal tumour in the sphenoid bone has been reported.<sup>27</sup>

Some patients with hemicrania continua report a history of mild to moderate head trauma and surgery.<sup>27,103</sup> The patients met the IHS criteria for chronic post-traumatic headache and displayed clinical signs typical of hemicrania continua. Furthermore, treatment with indomethacin, with doses up to 200 mg daily, was successful in all cases.

## Pathophysiology of hemicrania continua

Functional neuroimaging in hemicrania continua demonstrates activation of both the posterior hypothalamus and the dorsal rostral pons.<sup>105</sup> Posterior hypothalamic and brainstem activation are considered markers of TACs and migrainous syndromes respectively,<sup>106</sup> thus linking hemicrania continua to the pathophysiology of both cluster headache and migraine and mirroring hemicrania continua's clinical phenotype (overlap of TACs and migraine).

## Treatment

Indomethacin is usually totally effective in hemicrania continua and is included as part of its definition.<sup>1</sup> The vast majority (68%) of reported cases have indeed responded to indomethacin.<sup>103</sup> The results are dramatic, with a rapid onset of relief occurring within hours or 1–2 days, often with a dose response. Other non-steroidal anti-inflammatory drugs are less effective, although aspirin, ibuprofen, piroxicam-beta-cyclodextrin, diclofenac, cyclo-oxygenase 2 inhibitors and paracetamol have provided partial relief.<sup>107</sup> Although piroxicam-beta-cyclodextrin is inferior to indomethacin in hemicrania continua, its better tolerability may offer a good alternative for selected cases.<sup>108</sup> The triptans seem ineffective in hemicrania continua.

## Differential diagnosis of TACs

Given the predominant sensory system involved, referral patterns of TACs often involve orofacial structures and at times may primarily present in intraoral or unusual facial sites. Thus, cluster headache and paroxysmal hemicrania have caused misdiagnosis as dental pain, leading to unnecessary dental interventions.<sup>29,32,33,35</sup> Cluster headaches are often seen by ear, nose and throat surgeons and erroneously diagnosed as sinus pathology.<sup>29,32,33,35</sup>

Up to 10% of patients with paroxysmal hemicrania have pain triggered by neck movement,<sup>109</sup> causing confusion with musculoskeletal pain syndromes.

Regional tumours may cause TACs and have been discussed under individual entities. It is important to bear in mind that, although headache induced by tumour is rare, it may affect 0.8–5.9% of facial pain patients.<sup>110</sup>

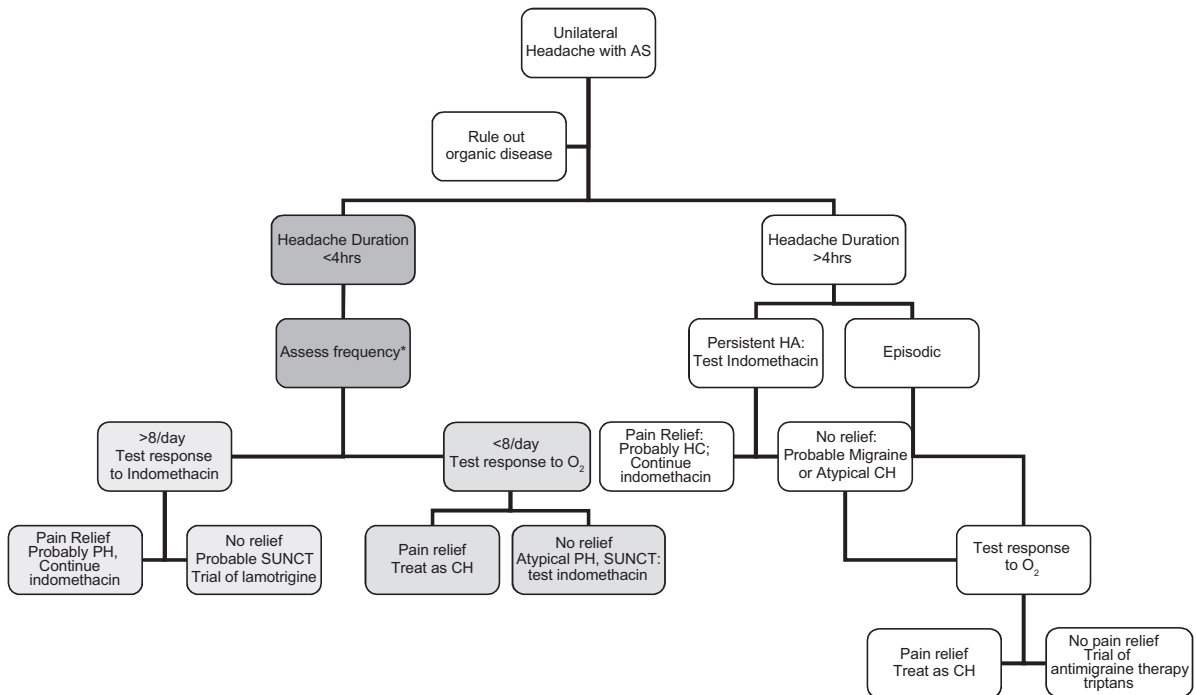
Trigeminal neuralgia affecting the ophthalmic, maxillary or mandibular branches accompanied by lacrimation has been reported.<sup>87,111</sup> These may mimic TACs, particularly SUNCT or even cluster headache.<sup>32,33</sup> However, SUNCT is typically resistant to trigeminal neuralgia therapy, has prominent and multiple autonomic signs<sup>111</sup> and has no refractory period.

The combination of cluster headache and trigeminal neuralgia in cluster-tic syndrome (CTS), although very rare, may cause particular diagnostic difficulties. Neck movements may precipitate pain in CTS (40%) and an atypical form of CTS has been described with very short attacks that make CTS disturbingly similar to paroxysmal hemicrania and even SUNCT.<sup>112</sup> Paroxysmal hemicrania has been associated with trigeminal neuralgia in a 'CPH-tic' syndrome; mixed attacks have also been described and may cause confusion with SUNCT.<sup>113</sup>

The similarities between all the neurovascular-type headaches may cause diagnostic difficulties. Moreover, patients rarely present with all the typical criteria as listed in the IHS classification.<sup>1</sup> Tables 1 and 2 summarize the various parameters in TACs, employing migraine as a reference point.

TAC location is the most confounding parameter in differential diagnosis (see Figure 2). Attack duration and frequency are probably the main features that distinguish TACs;<sup>1</sup> see Figures 3 and 4 and Table 1. Notwithstanding, there is often substantial overlap between TAC behaviour. Thus, a prolonged SUNCT attack may be just as lengthy as a short paroxysmal hemicrania attack that similarly may, at the other end of the spectrum, overlap with short cluster headache attacks (Figure 4). Relatively short migraine attacks may occur and, when dealing with a patient suffering





**Figure 5.** Flow diagram for the diagnosis of headaches with autonomic signs. Preliminary diagnosis is based on location and accompanying autonomic signs. This is followed by duration, frequency and treatment response, particularly to oxygen and indomethacin.

\* High-frequency triggered facial pain may also be trigeminal neuralgia with autonomic signs. AS, autonomic signs; CH, cluster headache; HA, headache; O<sub>2</sub>, oxygen; PH, paroxysmal hemicrania; SUNCT, short-lasting unilateral neuralgiform headache attacks with conjunctival injection and tearing.

from chronic migraine with autonomic features, differentiation from hemicrania continua may be difficult.<sup>114</sup>

Unilateral headache with ipsilateral autonomic signs lasting less than 2 minutes is highly likely to be SUNCT; TN accompanied by autonomic signs would be a second differential, particularly if a refractory period is present.<sup>115</sup> SUNA attacks may last considerably longer,<sup>96</sup> overlapping with short paroxysmal hemicrania. Headaches accompanied by autonomic signs lasting more than 4 hours are highly likely to be migraine, or a migraine variant with autonomic signs, especially in the upper third of the head.<sup>114,116</sup> More rarely cluster headache may last for up to 48 hours.<sup>29</sup> Two clear extremes in duration therefore become apparent: 2 minutes or less and 4 hours or more (see Figure 4). It is often difficult to distinguish long-lasting cluster headache with migrainous features from migraine. It is commonly accepted that cluster headache pain is more severe than migraine and similar to trigeminal neuralgia and SUNCT. Migraine attacks may ‘cluster’ or behave cyclically and overlap with more sustained cluster headache attacks.<sup>117</sup> Indeed the typical clustering or seasonal pattern of cluster headache is often observed in other headaches including hemicrania continua and paroxysmal hemicrania.<sup>64,118,119</sup> The majority of paroxysmal hemicrania

cases are characterized by chronic patterns that will differentiate them from the predominantly episodic nature of cluster headache.<sup>120</sup>

The flow diagram in Figure 5 is an attempt to help clinicians reach therapeutic decisions in the differentiation of unilateral headaches and facial pains with autonomic signs.

### Diagnostic utility of the treatment response of TACs

TACs are different in their response to therapy (see Table 2) and we often rely on this as a final endorsement of the diagnosis. A positive indomethacin response is considered highly indicative that the patient suffers from paroxysmal hemicrania or hemicrania continua.<sup>121,122</sup>

However, some overlap does occur in treatment response; for example, migraine and cluster headache may respond to indomethacin and triptans, whereas paroxysmal hemicrania and hemicrania continua may not. Atypical cases of cluster headache may not only respond to indomethacin but also present with unusual features.

In borderline cases, reaching an exact diagnosis may be academic and it is often best to commence therapy under a tentative diagnosis of TAC, and exploit treatment response and follow-up. Based on initial

grouping by duration and frequency, the clinician is often able to reach an accurate working diagnosis; see the algorithm in Figure 5. In unclear TAC cases it has been suggested that a trial of indomethacin is indicated.<sup>27</sup> However, given the low prevalence of paroxysmal hemicrania and hemicrania continua, the best approach is to instigate indomethacin treatment in patients with more than five attacks daily and/or with an attack duration of <30 minutes.

## Funding

This research received no specific grant from any funding agency in the public, commercial or not-for-profit sectors.

## References

1. *The international classification of headache disorders*, 2nd edition. Available at: <http://ihs-classification.org/en/> (2004, accessed 10 September 2011).
2. Larner AJ. Trigeminal autonomic cephalalgias: frequency in a general neurology clinic setting. *J Headache Pain* 2008; 9(5): 325–326.
3. Cittadini E and Matharu MS. Symptomatic trigeminal autonomic cephalalgias. *Neurologist* 2009; 15(6): 305–312.
4. Favier I, van Vliet JA, Roon KI, et al. Trigeminal autonomic cephalgias due to structural lesions: a review of 31 cases. *Arch Neurol* 2007; 64(1): 25–31.
5. Goadsby PJ, Cittadini E and Cohen AS. Trigeminal autonomic cephalalgias: paroxysmal hemicrania, SUNCT/SUNA, and hemicrania continua. *Semin Neurol* 2010; 30(2): 186–191.
6. Trucco M, Mainardi F, Maggioni F, et al. Chronic paroxysmal hemicrania, hemicrania continua and SUNCT syndrome in association with other pathologies: a review. *Cephalalgia* 2004; 24(3): 173–184.
7. Wilbrink LA, Ferrari MD, Kruit MC, et al. Neuroimaging in trigeminal autonomic cephalgias: when, how, and of what? *Curr Opin Neurol* 2009; 22(3): 247–253.
8. Gobel H, Czech N, Heinze-Kuhn K, et al. Evidence of regional protein plasma extravasation in cluster headache using Tc-99m albumin SPECT. *Cephalalgia* 2000; 20(4): 287.
9. Leone M and Bussone G. Pathophysiology of trigeminal autonomic cephalalgias. *Lancet Neurol* 2009; 8(8): 755–764.
10. Costa A, Ravaglia S, Sances G, et al. Nitric oxide pathway and response to nitroglycerin in cluster headache patients: plasma nitrite and citrulline levels. *Cephalalgia* 2003; 23(6): 407–413.
11. D'Amico D, Ferraris A, Leone M, et al. Increased plasma nitrites in migraine and cluster headache patients in interictal period: basal hyperactivity of L-arginine-NO pathway? *Cephalalgia* 2002; 22(1): 33–36.
12. Goadsby PJ and Edvinsson L. Human in vivo evidence for trigeminovascular activation in cluster headache: neuropeptide changes and effects of acute attacks therapies. *Brain* 1994; 117(3): 427–434.
13. Martins IP, Gouveia RG and Parreira E. Cluster headache without autonomic symptoms: why is it different? *Headache* 2005; 45(3): 190–195.
14. Leone M, Rigamonti A and Bussone G. Cluster headache sine headache: two new cases in one family. *Cephalalgia* 2002; 22(1): 12–14.
15. Lain AH, Caminero AB and Pareja JA. SUNCT syndrome: absence of refractory periods and modulation of attack duration by lengthening of the trigger stimuli. *Cephalalgia* 2000; 20(7): 671–673.
16. Lovely TJ, Kotsiakos X and Jannetta PJ. The surgical management of chronic cluster headache. *Headache* 1998; 38(8): 590–594.
17. Leone M and Bussone G. A review of hormonal findings in cluster headache: evidence for hypothalamic involvement. *Cephalalgia* 1993; 13(5): 309–317.
18. Holle D, Katsarava Z and Obermann M. The hypothalamus: specific or nonspecific role in the pathophysiology of trigeminal autonomic cephalalgias? *Curr Pain Headache Rep* 2011; 15(2): 101–107.
19. Matharu M and May A. Functional and structural neuroimaging in trigeminal autonomic cephalalgias. *Curr Pain Headache Rep* 2008; 12(2): 132–137.
20. Stillman M and Spears R. Endocrinology of cluster headache: potential for therapeutic manipulation. *Curr Pain Headache Rep* 2008; 12(2): 138–144.
21. Bartsch T, Levy MJ, Knight YE, et al. Differential modulation of nociceptive dural input to [hypocretin] orexin A and B receptor activation in the posterior hypothalamic area. *Pain* 2004; 109(3): 367–378.
22. Waldenlind E, Gustafsson SA, Ekblom K, et al. Circadian secretion of cortisol and melatonin in cluster headache during active cluster periods and remission. *J Neurol Neurosurg Psychiatry* 1987; 50(2): 207–213.
23. Leone M, Franzini A, Cecchini AP, et al. Hypothalamic deep brain stimulation in the treatment of chronic cluster headache. *Ther Adv Neurol Disord* 2010; 3(3): 187–195.
24. Frese A, Evers S and May A. Autonomic activation in experimental trigeminal pain. *Cephalalgia* 2003; 23(1): 67–68.
25. Goadsby PJ and Edvinsson L. Neuropeptide changes in a case of chronic paroxysmal hemicrania: evidence for trigemino-parasympathetic activation. *Cephalalgia* 1996; 16(6): 448–450.
26. Izumi H. Nervous control of blood flow in the orofacial region. *Pharmacol Ther* 1999; 81(2): 141–161.
27. Benoliel R and Sharav Y. Trigeminal autonomic cephalgias (TACs). In: Y Sharav and R Benoliel (eds) *Orofacial pain and headache*. Edinburgh: Mosby Elsevier, 2008; pp.223–254.
28. Manzoni GC, Terzano MG, Bono G, et al. Cluster headache: clinical findings in 180 patients. *Cephalalgia* 1983; 3(1): 21–30.
29. van Vliet JA, Eekers PJ, Haan J, et al. Features involved in the diagnostic delay of cluster headache. *J Neurol Neurosurg Psychiatry* 2003; 74(8): 1123–1125.
30. Manzoni GC, Micieli G, Granella F, et al. Cluster headache: course over ten years in 189 patients. *Cephalalgia* 1991; 11(4): 169–174.

31. Bahra A and Goadsby PJ. Diagnostic delays and mismanagement in cluster headache. *Acta Neurol Scand* 2004; 109(3): 175–179.
32. Klapper JA, Klapper A and Voss T. The misdiagnosis of cluster headache: a nonclinic, population-based, Internet survey. *Headache* 2000; 40(9): 730–735.
33. Van Alboom E, Louis P, Van Zandijcke M, et al. Diagnostic and therapeutic trajectory of cluster headache patients in Flanders. *Acta Neurol Belg* 2009; 109(1): 10–17.
34. Cademartiri C, Torelli P, Cologno D, et al. Upper and lower cluster headache: clinical and pathogenetic observations in 608 patients. *Headache* 2002; 42(7): 630–637.
35. Bahra A, May A and Goadsby PJ. Cluster headache: a prospective clinical study with diagnostic implications. *Neurology* 2002; 58(3): 354–361.
36. Torelli P and Manzoni GC. Pain and behaviour in cluster headache: a prospective study and review of the literature. *Funct Neurol* 2003; 18(4): 205–210.
37. Russell D. Cluster headache: severity and temporal profiles of attacks and patient activity prior to and during attacks. *Cephalalgia* 1981; 1(4): 209–216.
38. Pfaffenrath V, Pollmann W, Ruther E, et al. Onset of nocturnal attacks of chronic cluster headache in relation to sleep stages. *Acta Neurol Scand* 1986; 73(4): 403–407.
39. Chervin RD, Zallek SN, Lin X, et al. Timing patterns of cluster headaches and association with symptoms of obstructive sleep apnea. *Sleep Res Online* 2000; 3(3): 107–112.
40. Schurks M and Diener HC. Cluster headache and lifestyle habits. *Curr Pain Headache Rep* 2008; 12(2): 115–121.
41. Torelli P, Cologno D, Cademartiri C, et al. Possible predictive factors in the evolution of episodic to chronic cluster headache. *Headache* 2000; 40(10): 798–808.
42. Blau JN and Engel HO. Premonitory and prodromal symptoms in cluster headache. *Cephalalgia* 1998; 18(2): 91–93; discussion 71–72.
43. Langedijk M, van der Naalt J, Luijckx GJ, et al. Cluster-like headache aura status. *Headache* 2005; 45(1): 80–81.
44. Drummond PD. Dissociation between pain and autonomic disturbances in cluster headache. *Headache* 1990; 30(8): 505–508.
45. Wheeler SD. Significance of migrainous features in cluster headache: divalproex responsiveness. *Headache* 1998; 38(7): 547–551.
46. Irimia P, Cittadini E, Paemeleire K, et al. Unilateral photophobia or phonophobia in migraine compared with trigeminal autonomic cephalalgias. *Cephalalgia* 2008; 28(6): 626–630.
47. Manzoni GC. Cluster headache and lifestyle: remarks on a population of 374 male patients. *Cephalalgia* 1999; 19(2): 88–94.
48. Levy MJ, Matharu MS, Meeran K, et al. The clinical characteristics of headache in patients with pituitary tumours. *Brain* 2005; 128(8): 1921–1930.
49. Carter DM. Cluster headache mimics. *Curr Pain Headache Rep* 2004; 8(2): 133–139.
50. Fischera M, Marziniak M, Gralow I, et al. The incidence and prevalence of cluster headache: a meta-analysis of population-based studies. *Cephalalgia* 2008; 28(6): 614–618.
51. Sjaastad O and Bakkeiteig LS. Cluster headache prevalence: Vågå study of headache epidemiology. *Cephalalgia* 2003; 23(7): 528–533.
52. Dodick DW, Rozen TD, Goadsby PJ, et al. Cluster headache. *Cephalalgia* 2000; 20(9): 787–803.
53. Ashkenazi A and Schwedt T. Cluster headache: acute and prophylactic therapy. *Headache* 2011; 51(2): 272–286.
54. Rozen TD. Trigeminal autonomic cephalalgias. *Neurol Clin* 2009; 27(2): 537–556.
55. Rozen TD. High oxygen flow rates for cluster headache. *Neurology* 2004; 63(3): 593.
56. Antonaci F, Costa A, Candeloro E, et al. Single high-dose steroid treatment in episodic cluster headache. *Cephalalgia* 2005; 25(4): 290–295.
57. Paemeleire K, Evers S and Goadsby PJ. Medication-overuse headache in patients with cluster headache. *Curr Pain Headache Rep*. 2008; 12(2): 122–127.
58. Goadsby PJ, Cittadini E, Burns B, et al. Trigeminal autonomic cephalalgias: diagnostic and therapeutic developments. *Curr Opin Neurol* 2008; 21(3): 323–330.
59. Boes CJ and Dodick DW. Refining the clinical spectrum of chronic paroxysmal hemicrania: a review of 74 patients. *Headache* 2002; 42(8): 699–708.
60. Antonaci F and Sjaastad O. Chronic paroxysmal hemicrania (CPH): a review of the clinical manifestations. *Headache* 1989; 29(10): 648–656.
61. Matharu MS and Goadsby PJ. Bilateral paroxysmal hemicrania or bilateral paroxysmal cephalalgia, another novel indomethacin-responsive primary headache syndrome? *Cephalalgia* 2005; 25(2): 79–81.
62. Boes CJ, Vincent M and Russell D. Chronic paroxysmal hemicrania. In: J Olesen, PJ Goadsby and NM Ramadan et al. (eds) *The headaches*, 3rd edn. Philadelphia: Lippincott Williams & Wilkins, 2006, pp. 815–822.
63. Sarlani E, Schwartz AH and Greenspan JD et al. Chronic paroxysmal hemicrania: a case report and review of the literature. *J Orofac Pain* 2003; 17(1): 74–78.
64. Siow HC. Seasonal episodic paroxysmal hemicrania responding to cyclooxygenase-2 inhibitors. *Cephalalgia* 2004; 24(5): 414–415.
65. Sahota PK and Dexter JD. Sleep and headache syndromes: a clinical review. *Headache* 1990; 30(2): 80–84.
66. Benoliel R and Sharav Y. Paroxysmal hemicrania: case studies and review of the literature. *Oral Surg Oral Med Oral Pathol Oral Radiol Endod* 1998; 85(3): 285–292.
67. Pareja JA. Chronic paroxysmal hemicrania: dissociation of the pain and autonomic features. *Headache* 1995; 35(2): 111–113.
68. Cittadini E, Matharu MS and Goadsby PJ. Paroxysmal hemicrania: a prospective clinical study of 31 cases. *Brain* 2008; 131(4): 1142–1155.
69. Koopman JS, Dieleman JP, Huygen FJ, et al. Incidence of facial pain in the general population. *Pain* 2009; 147(1–3): 122–127.
70. Obermann M and Katsarava Z. Epidemiology of unilateral headaches. *Expert Rev Neurother* 2008; 8(9): 1313–1320.

71. Sjaastad O and Bakketeig LS. The rare, unilateral headaches: Vågå study of headache epidemiology. *J Headache Pain* 2007; 8(1): 19–27.
72. Cohen AS, Matharu MS and Goadsby PJ. Short-lasting unilateral neuralgiform headache attacks with conjunctival injection and tearing (SUNCT) or cranial autonomic features (SUNA): a prospective clinical study of SUNCT and SUNA. *Brain* 2006; 129(10): 2746–2760.
73. Kudrow DB and Kudrow L. Successful aspirin prophylaxis in a child with chronic paroxysmal hemicrania. *Headache* 1989; 29(5): 280–281.
74. Mariano da, Silva H, Benevides-Luz I, Santos AC, et al. Chronic paroxysmal hemicrania as a manifestation of intracranial parotid gland carcinoma metastasis: a case report. *Cephalalgia* 2004; 24(3): 223–227.
75. Gatzonis S, Mitsikostas DD, Ilias A, et al. Two more secondary headaches mimicking chronic paroxysmal hemicrania: is this the exception or the rule? *Headache* 1996; 36(8): 511–513.
76. Pareja J and Sjaastad O. Chronic paroxysmal hemicrania and hemicrania continua: interval between indomethacin administration and response. *Headache* 1996; 36(1): 20–23.
77. Sjaastad O and Antonaci F. Chronic paroxysmal hemicrania: a case report. Long-lasting remission in the chronic stage. *Cephalalgia* 1987; 7(3): 203–205.
78. Camarda C, Camarda R and Monastero R. Chronic paroxysmal hemicrania and hemicrania continua responding to topiramate: two case reports. *Clin Neurol Neurosurg* 2008; 110(1): 88–91.
79. Cohen AS and Goadsby PJ. Paroxysmal hemicrania responding to topiramate. *J Neurol Neurosurg Psychiatry* 2007; 78(1): 96–97.
80. Warner JS, Wamil AW and McLean MJ. Acetazolamide for the treatment of chronic paroxysmal hemicrania. *Headache* 1994; 34(10): 597–599.
81. Sjaastad O, Saunte C, Salvesen R, et al. Shortlasting unilateral neuralgiform headache attacks with conjunctival injection, tearing, sweating, and rhinorrhea. *Cephalalgia* 1989; 9(2): 147–156.
82. Sjaastad O and Kruszewski P. Trigeminal neuralgia and ‘SUNCT’ syndrome: similarities and differences in the clinical pictures. An overview. *Funct Neurol* 1992; 7(2): 103–107.
83. Pareja JA and Cuadrado ML. SUNCT syndrome: an update. *Expert Opin Pharmacother* 2005; 6(4): 591–599.
84. Pareja JA, Shen JM, Kruszewski P, et al. SUNCT syndrome: duration, frequency, and temporal distribution of attacks. *Headache* 1996; 36(3): 161–165.
85. Pareja JA, Caballero V and Sjaastad O. SUNCT syndrome: statuslike pattern. *Headache* 1996; 36(10): 622–624.
86. Baldacci F, Nuti A, Lucetti C, et al. SUNA syndrome with seasonal pattern. *Headache* 2009; 49(6): 912–914.
87. Benoliel R and Sharav Y. Trigeminal neuralgia with lacrimation or SUNCT syndrome? *Cephalalgia* 1998; 18(2): 85–90.
88. Kruszewski P, Zhao JM, Shen JM, et al. SUNCT syndrome: forehead sweating pattern. *Cephalalgia* 1993; 13(2): 108–113.
89. Benoliel R and Sharav Y. SUNCT syndrome: case report and literature review. *Oral Surg Oral Med Oral Pathol Oral Radiol Endod* 1998; 85(2): 158–161.
90. Matharu MS, Cohen AS, Boes CJ, et al. Short-lasting unilateral neuralgiform headache with conjunctival injection and tearing syndrome: a review. *Curr Pain Headache Rep* 2003; 7(4): 308–318.
91. D’Andrea G and Granella F. SUNCT syndrome: the first case in childhood. Short-lasting unilateral neuralgiform headache attacks with conjunctival injection and tearing. *Cephalalgia* 2001; 21(6): 701–702.
92. Gantenbein AR and Goadsby PJ. Familial SUNCT. *Cephalalgia* 2005; 25(6): 457–459.
93. Jacob S and Rajabally Y. Short-lasting unilateral neuralgiform headache with cranial autonomic symptoms (SUNA) following vertebral artery dissection. *Cephalalgia* 2007; 27(3): 283–285.
94. Jimenez Caballero PE, Portilla Cuenca JC and Casado Naranjo I. Short-lasting unilateral neuralgiform headache attacks with cranial autonomic symptoms (SUNA) secondary to epidermoid cyst in the right cerebellopontine angle successfully treated with surgery. *J Headache Pain* 2011; 12(3): 385–387.
95. Pareja JA, Kruszewski P and Sjaastad O. SUNCT syndrome: trials of drugs and anesthetic blockades. *Headache* 1995; 35(3): 138–142.
96. Williams MH and Broadley SA. SUNCT and SUNA: clinical features and medical treatment. *J Clin Neurosci* 2008; 15(5): 526–534.
97. Koseoglu E, Karaman Y, Kucuk S. SUNCT syndrome associated with compression of trigeminal nerve. *Cephalalgia* 2005; 25(6): 473–475.
98. Morales-Asin F, Espada F, Lopez-Obarrio LA, et al. A SUNCT case with response to surgical treatment. *Cephalalgia* 2000; 20(1): 67–68.
99. Pareja JA and Sjaastad O. SUNCT syndrome: a clinical review. *Headache* 1997; 37(4): 195–202.
100. Rossi P, Faroni J, Tassorelli C. Diagnostic delay and suboptimal management in a referral population with hemicrania continua. *Headache* 2009; 49(2): 227–234.
101. Newman LC, Lipton RB and Solomon S. Hemicrania continua: ten new cases and a review of the literature. *Neurology* 1994; 44(11): 2111–2114.
102. Newman LC, Lipton RB, Russell MS. Hemicrania continua: attacks may alternate sides [see comments]. *Headache* 1992; 32(5): 237–238.
103. Peres MF, Silberstein SD, Nahmias S. Hemicrania continua is not that rare. *Neurology* 2001; 57(6): 948–951.
104. Peres MF, Siow HC, and Rozen TD. Hemicrania continua with aura. *Cephalalgia* 2002; 22(3): 246–248.
105. Matharu MS, Cohen AS, McGonigle DJ, et al. Posterior hypothalamic and brainstem activation in hemicrania continua. *Headache* 2004; 44(8): 747–761.
106. May A. New insights into headache: an update on functional and structural imaging findings. *Nat Rev Neurol* 2009; 5(4): 199–209.
107. Peres MF and Silberstein SD. Hemicrania continua responds to cyclooxygenase-2 inhibitors. *Headache* 2002; 42(6): 530–531.



108. Sjaastad O and Antonaci F. A piroxicam derivative partly effective in chronic paroxysmal hemicrania and hemicrania continua. *Headache* 1995; 35(9): 549–550.
109. Sjaastad O, Egge K and Horven I et al. Chronic paroxysmal hemicranial: mechanical precipitation of attacks. *Headache* 1979; 19(1): 31–36.
110. Bullitt E, Tew JM and Boyd J. Intracranial tumors in patients with facial pain. *J Neurosurg* 1986; 64(6): 865–871.
111. Pareja JA, Baron M, Gili P, et al. Objective assessment of autonomic signs during triggered first division trigeminal neuralgia. *Cephalalgia* 2002; 22(4): 251–255.
112. Alberca R and Ochoa JJ. Cluster tic syndrome. *Neurology* 1994; 44(6): 996–999.
113. Boes CJ, Matharu MS and Goadsby PJ. The paroxysmal hemicrania-tic syndrome. *Cephalalgia* 2003; 23(1): 24–28.
114. Kaup AO, Mathew NT, Levyman C, ‘Side locked’ migraine and trigeminal autonomic cephalgias: evidence for clinical overlap. *Cephalalgia* 2003; 23(1): 43–49.
115. Simms HN and Honey CR. The importance of autonomic symptoms in trigeminal neuralgia. *J Neurosurg*. 2011; 115(2): 210–6.
116. Dora B. Migraine with cranial autonomic features and strict unilaterality. *Cephalalgia* 2003; 23(7): 561–562.
117. Fox AW and Davis RL. Migraine chronobiology. *Headache* 1998; 38(6): 436–441.
118. Peres MF, Stiles MA, Oshinsky M, et al. Remitting form of hemicrania continua with seasonal pattern. *Headache* 2001; 41(6): 592–594.
119. Veloso GG, Kaup AO, Peres MF, et al. Episodic paroxysmal hemicrania with seasonal variation: case report and the EPH-cluster headache continuum hypothesis. *Arq Neuropsiquiatr* 2001; 59(4): 944–947.
120. Zidverc-Trajkovic J, Pavlovic AM, Mijajlovic M, et al. Cluster headache and paroxysmal hemicrania: differential diagnosis. *Cephalalgia* 2005; 25(4): 244–248.
121. Boes C. Differentiating paroxysmal hemicrania from cluster headache. *Cephalalgia* 2005; 25(4): 241–243.
122. Matharu MS, Boes CJ and Goadsby PJ. Management of trigeminal autonomic cephalgias and hemicrania continua. *Drugs*. 2003; 63(16): 1637–77.

## Questions

1. **A patient complains of a unilateral, periorbital and maxillary pain lasting 5 minutes and accompanied by lacrimation and a red eye. What is the most likely diagnosis?**
  - a. Cluster headache
  - b. Hemicrania continua
  - c. Paroxysmal hemicrania
  - d. SUNCT
2. **A patient presents with a unilateral, strong headache lasting 20 minutes and accompanied by ipsilateral lacrimation. He responds significantly to oxygen at 10 litres/minute. What is the most likely diagnosis?**
  - a. Cluster headache
  - b. Hemicrania continua
  - c. Paroxysmal hemicrania
  - d. SUNCT
  - e. Classical trigeminal neuralgia
3. **What is the drug of choice for hemicrania continua?**
  - a. Propranolol
  - b. Verapamil
  - c. Indomethacin
  - d. Naproxen sodium
  - e. Ibuprofen
4. **Migraine-type features are most likely to occur in:**
  - a. cluster headache
  - b. hemicrania continua
  - c. paroxysmal hemicrania
  - d. SUNCT
  - e. (a) and (b)
5. **Which abortive pharmacological treatment option is the most effective for episodic cluster headache?**
  - a. Indomethacin
  - b. Zolmitriptan
  - c. Sumatriptan (subcutaneous)
  - d. Sumatriptan (intranasal)
  - e. Verapamil